

1

APPARENT MODE **NAT ACC SUIC HOMI**

STATE HOSP O.I.S. AUTOPSY WAIVER CLOSELY WATCHED DOMESTIC VIOLENCE

IN CUSTODY AT WORK LAW ENFORCEMENT RELATED VICTIMS OF CRIME GANG RELATED

SPECIAL CIRCUMSTANCES **DRIVE-BY**

MULTIPLE **GSW'S**

CASE NO **97-01812**

CRYPT **III**

LAST, FIRST MIDDLE **WALLACE, CHRISTOPHER GEORGE LATORE**

AKA: JOHN JANE UND # **N/A**

ADDRESS **5 ELLIOT COURT** CITY **TEANECK, NJ.** STATE ZIP

EX **M** RACE **B** DOB **6-21-72** AGE **24** HGT **74** WGT **395** EYES **BRO** HAIR **BLK** TEETH **OWN** ID VIEW YES NO **VIEWABLE**

BEARD Y N MUSTACHE Y N JINSHAVEN Y N

SCARS (DESCRIBE) **(VERY SPARSE)** MARKS **(R) INSIDE FOREARM** TATTOOS (DESCRIBE) **[]** AMPUTATIONS **"THE LORD IS MY LIGHT AND MY SALVATION..."** PIERCINGS **FAIRFAX** DEFORMITIES

LOCAL ADDRESS **TEANECK, NJ** CITY STATE ZIP **07112**

RELATIONSHIP **PRESENT @ HOSP.** NOTIFIED BY YES NO DATE TIME

SSN MULT. DL ID **NONE** STATE **N/A** PENDING BY **N/A**

PRINTS BY: VISUAL (SEE BELOW) LAPD PRINTS DOJ PRINTS FAMILY @ HOSPITAL LASD PRINTS CAL ID PRINTS DL/ID FBI PRINTS **BY WIFE & MOTHER NCIC PRINT CLASS ✓ 340972**

A # MAIN # C-I # FBI # MILITARY # **774795MAB** **NY**

JAMF (PRINT) SIGNATURE RELATIONSHIP PHONE

I HAVE PERSONALLY SEEN THE DECEASED OR A PHOTOGRAPH AND CONFIRM THE IDENTIFICATION

PLACE OF DEATH/PLACE FOUND **CECILIUS - SINAI MEDICAL CENTER** ADDRESS OR LOCATION **8700 BEVERLY BLVD., LA 90048** CITY ZIP

PLACE OF INJURY **VEHICLE** AT WORK YES NO DATE **3-9-97** TIME **0030** LOCATION OR ADDRESS **N/B FAIRFAX @ WILSHIRE LOS ANGELES, CA 90048** ZIP

FOUND BY **DR. PAUL SILKA** FOUND BY (PRON. BY)

OTHER AGENCY & INV. OFFICER **APD/WILSHIRE DET.'S SCOTT & COOPER** PHONE REPORT NO. NOTIFIED BY NO

TRANSPORTED BY: **CARLOS GARCIA / GREG MYERS** TO: FSC AVRO SCVRO DATE **3-9-97** TIME **0830**

PRINTS YES NO CLOTHING YES NO PA RPT YES NO MEC SEAL PA SEAL **(NOT SEALED)** MORTUARY

INVEST. PHOTO # YES NO EVIDENCE LOG YES NO PROP: YES NO HOSP. RPT. YES NO HOSP. CHART YES NO PF NO. **966265**

BUCHSIDE NOTE YES NO GSR NO **A9117** RCPT. NO. **144609**

SYNOPSIS: **PER DET. FELIX AND FAMILY, INCIDENT WAS A PASSENGER, (R) FRONT SEAT OF A SUBURBAN TRAV. N/B FAIRFAX, DRIVEN BY DECID'S COUSIN DAMIAN POTLER. THE VEH STOPPED AT THE LIGHT AT THE 1/3 WITH WILSHIRE BLVD. AND AN UNK VEH DROVE UP ON THE (R) SIDE AND OPENED FIRE. DECID WAS IMMEDIATELY DRIVEN TO HOSPITAL AND LATER PRONOUNCED.**

INVESTIGATOR **Shelby L. Johnson #411487** DATE **3-9-97** REVIEWED BY: DATE TIME

82

- Accident
- Homicide
- Suicide
- Questionable Accident/Homicide
- Questionable Accident/Suicide
- Questionable Suicide/Homicide
- Investigator Requests Rush

Kit #
A-9117

97-01812
WALLACE, CHRISTOPHER
HOMICIDE III
LAPD/WILSHIRE

INFORMATION ABOUT DECEDENT/SHOOTING

Right Handed Left Handed Unknown Male Female

Occupation _____ Unknown

Activity Prior to Shooting RIDING IN FT PASS SEAT OF VEH

Have the decedent's hands been touched by anyone prior to taking the GSR sample? Yes No Unknown
If yes, by whom? Paramedics Family Police Hospital Personnel
 Other _____

Was the weapon found in the decedent's hand? Yes No Unknown - Moved prior arrival
If yes, which one? Right Left
If no, describe weapon's location in relationship to decedent _____

Shooting Occurred: Indoors Outdoors Unknown FROM VEH

Location of Body: Indoors Outdoors Automobile Hospital
Other _____

Number of Shots Fired: MULTIPLE

Date 3-9-97 and Time 0030 of Shooting

Date 3-9-97 and Time 0900 GSR samples were taken.

GSR evidence collected At Scene At FSC At Hospital
 Other _____ By: CARLOS GARCIA #233798

Body transported to FSC via Coroner Contractor _____

FIREARM

Revolver Semi-automatic/automatic Rifle Shotgun

Other _____

Make/Model _____ Caliber _____

AMMUNITION

Brand of Ammunition _____ Caliber of Ammunition _____

Bullet Configuration: Round Nose Hollow Point Wad Cutter Pointed
Other _____

Bullet Surface: Jacketed Semi-jacketed Bare Lead Plated

Comments: _____

Investigator [Signature] Date 3-9-97

Do not write below this line

RESULTS:

White: Medical file
Pink: Laboratory Copy
Yellow: Laboratory Copy


12

AUTOPSY REPORT

No.

97-01812

WALLACE, CHRISTOPHER

I performed an autopsy on the body of  the DEPARTMENT OF CORONER

at Los Angeles, California on MARCH 10, 1997 @ 1030 HOURS
(Date) (Time)

From the anatomic findings and pertinent history I ascribe the death to:

(A) **GUNSHOT WOUND TO ABDOMEN--CHEST**

DUE TO, OR AS A CONSEQUENCE OF

(B)

DUE TO, OR AS A CONSEQUENCE OF

(C)

DUE TO, OR AS A CONSEQUENCE OF

(D)

OTHER CONDITIONS CONTRIBUTING BUT NOT RELATED TO THE IMMEDIATE CAUSE OF DEATH

MULTIPLE NONFATAL GUNSHOT WOUNDS

Anatomical Summary:

I. Multiple gunshot wounds.

- A. Gunshot wound #1 to left forearm, penetrating, nonfatal; soft tissue injury only; bullet recovered.
- B. Gunshot wound #2 to soft tissue of back, perforating, nonfatal; no projectile recovered.
- C. Gunshot wound #3 to soft tissue of left thigh, perforating; superficial laceration of scrotum; nonfatal, no projectile recovered.
- D. Gunshot wound #4 to abdomen-chest, penetrating, fatal; perforating injuries to ascending colon, liver, right hemidiaphragm, pericardium, heart and upper lobe of left lung; bullet recovered from anterior left shoulder area.

II. Other findings.

- A. Morbid obesity (395 pounds).
 - 1. Cardiomegaly (660 grams) with biventricular hypertrophy.
 - 2. Hepatosplenomegaly (liver 2280 grams, spleen 260 grams).
 - 3. Thyroidomegaly (120 grams).

12**AUTOPSY REPORT**

No.

97-01812

WALLACE, CHRISTOPHER

Page 2

- B. Pulmonary edema, moderate.
- C. Cerebral edema, mild to moderate.
- D. Cholelithiasis (cholesterol type stones).
- E. Status post left femoral fracture with placement of orthopedic rod, remote.
- F. Status post emergent medical and surgical intervention.
 - 1. Clinical history of hemothorax and hemopericardium.

III. See Toxicology report.

CIRCUMSTANCES:

The following information is obtained from Coroner's Forms 1 and 18 as well as medical records. This 24-year-old male was a passenger in a vehicle when he was shot in a drive-by incident at approximately 0030 hours on 3-9-97. He was taken to Cedars-Sinai Hospital, arriving in the emergency room at approximately 0048 hours in full arrest and with agonal rhythm. An emergency thoracotomy revealed a large amount of blood and in the chest and in the pericardium, all of which was evacuated. Intracardiac massage and internal defibrillations were performed, with no response, and he was officially pronounced dead at 0115 hours.

Medical records indicate that a bullet was found at the hospital when the body was turned over after pronouncement of death; according to records, this was given to the police. According to LAPD Wilshire Division Detectives Chavez and Balderrama, two bullets were recovered from the hospital, each of which was found on the gurney on which the decedent was lying. The same detectives also reported to the examiner that the bullets passed through a car door before striking the decedent.

EVIDENCE OF INJURY:

The gunshot wounds are arbitrarily numbered for the convenience of the examiner and do not indicate a sequence of injury. No

12**AUTOPSY REPORT**

No.

97-01812

WALLACE, CHRISTOPHER

Page 3

soot or stippling is noted in association with any of the entrance gunshot wounds.

Gunshot wound #1:

The entrance wound is located on the dorsal left forearm close to the olecranon process (point of the elbow), 14-1/4 inches from the apex of the shoulder and 5/8 inch distal to the olecranon process. The slightly irregular, ovoid defect measures 15/16 x 1/4 inch and is abraded on all but its most distal aspect. Abrasion rim is largest proximally (3/16 inch maximal width) and at the ulnar aspect (1/4 inch maximal width).

The projectile follows a proximal to distal, slightly dorsal to volar and minimally radial trajectory through the soft tissue of the forearm, passing through soft tissue and muscle. There is no evident fracture of the ulna. The projectile comes to rest approximately 10-1/2 inches distal to the entrance defect in the ulnar aspect of the distal forearm close to the wrist. The projectile is located volar to the ulna. The track is explored and/or probed from beginning to end, showing a mild to moderate amount of hemorrhage along it. There is no evident injury to the ulnar artery.

The bullet is recovered from the above location at 1058 hours. It is a medium caliber lead bullet with a full copper jacket open at the base. The bullet appears slightly compressed. The base is marked with "LS" for identification purposes, and it is placed into evidence envelope #1. A small piece of dark fabric, present at the edge of the entrance wound, is recovered and placed in the same evidence envelope.

This is a nonfatal wound since it involves only injury to soft tissue and muscle, with no major vascular involvement.

Gunshot wound #2:

The entry wound is located on the back, 20-3/8 inches from the top of the head and 3-1/2 inches left of midline. The ovoid defect measures 1/4 x 5/16 inch and is abraded on inferior-medial aspect only, to a maximal width of 5/16 inch. The projectile follows a back to front, right to left and upward

12**AUTOPSY REPORT**

No.

97-01812

WALLACE, CHRISTOPHER

Page 4

trajectory, passing shallowly across the soft tissues and muscles of the back towards the left shoulder area. It does not enter the left chest cavity, nor does it fracture any of the ribs or the scapula. (Note: the track is explored along its entirety between the entrance and exit wounds; hemorrhage is present along the track but no other injury is identified). The projectile exits the apex of the left shoulder 8-3/4 inches left of anterior midline. The exit wound originally appears as a gaping, 1/4 x 5/16 inch slit-like defect; when the edges are apposed, the defect measures approximately 3/8 inch. The edges are abraded in the anterior-lateral aspect, to a maximal width of 1/4 inch. Edges appose easily. No projectile is recovered.

This is a nonfatal gunshot wound since injury involves soft tissue only.

Gunshot wound #3:

The entry wound is located on the posterior left thigh, 47-1/4 inches from the top of the head, slightly medial to the vertical midline of the thigh. The entrance defect is circular, with a diameter of 5/16 inch. It is surrounded by a continuous margin of abrasion that is largest medially, where it measures 1/8 inch.

The projectile follows a back to front, left to right and upward trajectory, passing through the adipose tissue and muscle of the posterior and medial aspects of the thigh without injuring the femoral vessels. (Note: the majority of the path is dissected, revealing a hemorrhagic track through the soft tissue; only the most anterior portion of the track is examined by probing). The projectile exits the anterior left thigh medially and proximally, 41-3/4 inches from the top of the head, close to the groin. The exit defect is a 1/2 inch linear slit-like defect with non-abraded, apposable edges. After exiting, the projectile strikes the left side of the scrotum, causing a very shallow, 3/8 inch linear laceration located 2 inches left of midline. This defect only involves the most superficial aspect of skin (epidermis), with minimal penetration. There is a small amount of hemorrhage in the area. This portion of the scrotum lies directly over the exit defect of the left thigh.

12**AUTOPSY REPORT**

No.

97-01812

WALLACE, CHRISTOPHER

5

Page _____

No projectile is recovered. This is considered a nonfatal wound because the track involves tissue only, with no major vascular involvement.

Gunshot wound #4:

The entrance wound is located on the anterolateral right hip, 30 inches from the top of the head and 12 inches right of anterior midline. It is a slightly irregular, ovoid defect measuring $1/2 \times 5/16$ inch. It is surrounded by a continuous, slightly irregular margin of abrasion that is minimal posteriorly and largest in the anterior-inferior aspect, where it has a maximal width of $1/4$ inch.

The projectile follows a right to left, slightly back to front and upward trajectory through the abdomen and chest areas. It initially passes through the soft tissue of the right hip area, with no injury to the pelvis, entering the peritoneum in the right lower quadrant. It perforates the ascending colon and the liver, entering the liver inferiorly and exiting it superiorly. It then perforates the right hemidiaphragm and the overlying basilar pericardium. It perforates the heart, entering it at the right atrium near the inferior vena cava, perforating the ventricular septum in the subvalvular area, then exiting the anterior left ventricular wall. The projectile then re-perforates the pericardium and perforates the medial aspect of the upper lobe of the left lung. It then exits the left chest cavity anteriorly by passing through the 3rd rib, which is fractured. It then perforates the soft tissue and muscle of the left pectoral area, passing through the axillary area to come to rest subcutaneously in the anterior left shoulder area.

The projectile is recovered in the anterior left shoulder area, $14-1/4$ inches from the top of the head and $9-3/4$ inches left of midline, with the subcutaneous adipose tissue, at 1150 hours. It is a medium caliber lead bullet with a full copper jacket that remains open at the base. The bullet appears deformed (flattened) at the nose. The base is marked "LS" for identification purposes, and the bullet is placed into evidence envelope #2.

This is considered a fatal wound due to the multiple visceral injuries (colon, liver, heart, left lung).

12**AUTOPSY REPORT**

No.

97-01812

WALLACE, CHRISTOPHER

6

Page _____

EVIDENCE OF MEDICAL INTERVENTION:

A coarsely sutured thoracotomy incision passes below the left breast and enters the left chest cavity through the 6th intercostal space. There is an unsutured cutdown incision in the right groin packed with gauze. There are multiple needle punctures in the right antecubital fossa. A hospital identification bracelet is around the left wrist. Internally, the pericardium has been incised. None of the internal injuries has been repaired.

At the lateral edge of the left breast near the axilla is an irregular, ovoid, shallow skin laceration with minimal to no hemorrhage associated with it, consistent with that having been made by a rib spreader.

IDENTIFYING FEATURES:

One tattoo is identified, located on the volar right forearm. This large tattoo consists of a scroll containing a long verse from the bible, identified on the tattoo as Psalm 27.

There is a well-healed, arcuate old surgical scar in the left posterior hip area. Slightly above it on the lateral left back is smaller, well-healed apparently surgical scar. On the lateral left thigh, slightly above the knee is a very small well-healed old surgical scar. Postmortem x-ray reveals a left femoral mid-shaft fracture and the presence of an orthopedic rod along the left femur, with screws at the proximal and distal ends.

On the dorsal left wrist is a linear well-healed old surgical scar. On the lateral right ankle are ill-defined, hyperpigmented and hypopigmented nonspecific old scars. On the medial left calf and the left anterior shin area are several irregular, flat, hyperpigmented nonspecific scars.

EXTERNAL EXAMINATION:

The body is that of an unembalmed Black male adult who appears the stated age of 24 years. The body is identified by toe tags.

12**AUTOPSY REPORT**

No.

97-01812

WALLACE, CHRISTOPHER

Page 7

The overall appearance of the body is consistent with the recorded height of 74 inches and the recorded weight of 395 pounds. The body appears severely obese, with an extremely protuberant abdomen, and is normally muscular. Skin is essentially unremarkable except for the presence of a few small acrochordons (skin tags) at the right and left bases of the neck, and a slightly larger skin tag on the right side of the scrotum. The occipital scalp contains a large area of nonspecific dermatitis with focal mild hair loss and the presence of multiple small, ill-defined nodules on the scalp. Livor mortis is distributed dorsally and is fixed. Rigor mortis is not present and presumably has been altered/abolished by prior handling during photography and transportation.

The head is normocephalic and is covered by short, tightly curled black hair with no appreciable balding. There is a thin mustache but no beard. Examination of the eyes reveals brown irides, equal round pupils and extremely injected but otherwise unremarkable sclerae. There are no petechial hemorrhages of the conjunctivae of the eyelids or sclerae. The ears and external auditory canals are unremarkable; earlobes are not pierced. There is a small amount of blood in the nares, without obstruction. The oral cavity is unobstructed. Upper and lower natural teeth are present. The neck is unremarkable. There are no resuscitative marks over the precordium. There is no appreciable chest deformity or increased anterior-posterior chest diameter. There are no scars of the chest or abdomen. The abdomen is extremely protuberant due to obesity and contains multiple pale striae anteriorly. The genitalia are those of a circumcised adult male. There is no evidence of trauma to the genitalia or to the anus. No needle tracks are identified. There are no needle punctures that do not appear related to therapeutic procedures. There is no edema of the extremities and no joint deformities are identified.

CLOTHING:

The body is unclothed and no clothing accompanies the body to the Forensic Science Center.

12**AUTOPSY REPORT**

No.

97-01812

WALLACE, CHRISTOPHER

8

Page _____

INITIAL INCISION:

The body cavities are entered through a Y-shaped incision. Additional incisions are made in the following areas in order to explore them for injury and/or to recover projectiles: left side of back and shoulder, posterior left thigh, volar left forearm.

Examination of the gingiva, lips and oral mucosa reveals no lesions and no evidence of trauma. Examination of the tongue reveals a small amount of hemorrhage at the right edge of the middle third, without accompanying laceration; this is consistent with intubation. No other lesion or trauma is present. The hyoid bone and larynx are intact without fractures. There is no hemorrhage in the adjacent throat organs or in the prevertebral fascia. Both pleural cavities are free of adhesions. Each contains a very small amount of liquid blood (Note: a thoracotomy has been performed). There are no rib fractures or parietal pleural defects other than those previously described in association with the gunshot injury and the therapeutic thoracotomy. There is no evidence of pneumothorax. The lungs appear fairly well expanded. Soft tissues of the thoracic and abdominal walls are well-preserved. The organs of the abdominal cavity have a normal arrangement. None is absent. There is a small amount of blood in the abdominal cavity (visually estimated at no greater than 50 cc, liquid with small clots). There is no evidence of peritonitis and there are no peritoneal adhesions.

SYSTEMIC AND ORGAN REVIEW

The following observations are limited to findings other than the injuries and/or changes described above.

CARDIOVASCULAR SYSTEM:

The aorta is elastic and of even caliber throughout with vessels distributed normally from it. No aneurysms are present. The intimal surface shows moderate fatty streaking and mild diffuse hemoglobin staining, the latter consistent with very early decompositional change.

12**AUTOPSY REPORT**

No.

97-01812

WALLACE, CHRISTOPHER

Page 9

The pericardium has been previously incised. The heart weighs 660 grams and appears prominently enlarged. There is biventricular hypertrophy. Wall thicknesses are as follows: right ventricle 0.4 to 0.6 cm, left ventricle 1.7 to 2.1 cm, interventricular septum 2.0 cm. The chambers are normally developed and there are no mural thrombi within them. There are no congenital septal defects. The valves are thin, leafy and competent. There is no abnormality of the apices of the papillary muscles. There is no appreciable endocardial hemoglobin staining. The great vessels enter and leave in a normal fashion. The ductus arteriosus is obliterated. The foramen ovale is closed. The coronary ostia are widely patent. The coronary arteries have a normal pattern of distribution with right dominance. The coronary arteries are widely patent and show minimal atherosclerosis with no significant stenosis. The myocardium contains no focal lesions exclusive of trauma.

RESPIRATORY SYSTEM:

There is no edema of the larynx and there are no fractures of the laryngeal cartilages. The posterior pharynx contains moderately prominent pharyngeal tonsils bilaterally. There is no blood or other material within the trachea or major bronchi. The mucosal surfaces of the respiratory passages are intact and unremarkable. The right lung weighs 690 grams and the left lung weighs 600 grams. Both are subcrepitant. Visceral pleurae are smooth and intact (exclusive of the gunshot injuries on the left). Sectioning reveals moderate edema and congestion bilaterally. There is no evidence of consolidation and there are no focal lesions exclusive of trauma. There is no evidence of thromboembolism within the pulmonary vasculature.

GASTROINTESTINAL SYSTEM:

The esophagus is intact throughout and is grossly unremarkable. The stomach is not distended. It contains up to 50 cc of thin, green-brown liquid. No residual medication or capsular material is identified. The gastric mucosa is unremarkable. The small intestine and colon are unremarkable on external and in-situ examination (exclusive of the gunshot injury to the ascending colon, previously described). The small intestine and colon are opened along their entire length and are unremarkable throughout.

12**AUTOPSY REPORT**

No.

97-01812

WALLACE, CHRISTOPHER

Page 10

Luminal contents are normal in color and consistency. The appendix is present and is grossly unremarkable. The pancreas occupies a normal position. Sectioning reveals no parenchymal abnormality. There is very mild autolytic softening and discoloration of the parenchyma. Pancreatic ducts are not ectatic.

HEPATOBIILIARY SYSTEM:

The liver weighs 2280 grams and appears enlarged. It is red-brown. The capsule and parenchyma are unremarkable exclusive of injury. The cut surface is smooth and has a normal consistency. There is no evidence of fatty change or fibrosis on gross examination. The gallbladder has a thin, pliable wall and contains between 30 and 50 cc of green bile. Within it are five yellow, ovoid, morula-shaped, soft gallstones with maximal diameters between 0.4 and 0.6 cm. No stones are present in the cystic duct. There is no obstruction or dilatation of the extrahepatic ducts. Periportal lymph nodes are not appreciably enlarged.

URINARY SYSTEM:

Each kidney weighs 260 grams. Both are normally situated and the capsules strip easily to reveal smooth cortical surfaces. Corticomedullary demarcation is sharp. The parenchyma appears slightly congested in the cortical areas and extremely congested in the medullary pyramids. No focal lesions are noted in any area. Peripelvic fat is not increased. Ureters show no evidence of dilatation or obstruction and pursue their normal course. The urinary bladder is unremarkable. It contains a minimal amount of yellow urine.

MALE GENITAL SYSTEM:

The prostate shows no evidence of enlargement or nodularity. Both testes are in the scrotum, are atraumatic and contain no focal lesions.

12**AUTOPSY REPORT**

No.

97-01812

WALLACE, CHRISTOPHER

Page 11**HEMOLYMPHATIC SYSTEM:**

The spleen appears mildly enlarged and weighs 260 grams. The capsule is smooth and intact. The parenchyma is dark red, diffusely congested, and contains no focal lesions. Lymph nodes throughout the body are small and inconspicuous. Bone is unremarkable. Bone marrow is the usual appearance for age.

ENDOCRINE SYSTEM:

The thyroid appears diffusely and symmetrically enlarged, weighs 120 grams, and is unremarkable on sectioning with no evidence of nodularity or focal lesion. Both adrenal glands show very early medullary autolysis but are otherwise unremarkable. The thymus is the usual appearance for age. The pituitary gland is unremarkable.

CENTRAL NERVOUS SYSTEM:

There is no hemorrhage beneath the scalp, into the orbits or into the temporal muscles. There are no fractures of the calvarium or base of the skull. There are no tears of the dura mater and there are no epidural, subdural or subarachnoid hematomas. The brain weighs 1490 grams and appears mildly to moderately edematous. Leptomeninges are unremarkable. The convolutionary pattern is within normal limits. The cerebral hemispheres are symmetrical. Coronal sectioning demonstrates a uniformity of cortical gray thickness. There is no softening, discoloration or hemorrhage of the white matter. Basal ganglia are intact. Anatomic landmarks are preserved. The ventricular system, brain stem and cerebellum are unremarkable. There is no evidence of uncal or cerebellar herniation. Vessels at the base of the brain have a normal pattern of distribution and are free of aneurysms and atherosclerosis. The spinal cord is not dissected.

HISTOLOGIC SECTIONS:

Representative sections from various organs are preserved in 10% formalin and placed in a storage jar.

12**AUTOPSY REPORT**

No.

97-01812

WALLACE, CHRISTOPHER

Page 12

TOXICOLOGY:

Blood, bile, minimal urine, liver tissue and stomach contents have been submitted to the laboratory. A homicide screen has been requested.

PHOTOGRAPHS:

Photographs have been taken prior to and during the course of the autopsy.

RADIOLOGY:

The body has been fluoroscoped and 9 x-rays have been taken.

DIAGRAMS USED:


Diagrams 20 (3 sets) and 21 have been used in the preparation of this autopsy report.

WITNESSES:

LAPD Wilshire Division Detectives Balderrama and Chavez were present at the autopsy.

OPINION:

The cause of death is a penetrating gunshot wound to the abdomen and chest, causing multiple visceral injuries (gunshot wound #4). In addition, the decedent received 3 gunshot wounds (left forearm, left thigh and back) that were not considered fatal wounds due to the absence of visceral or major vascular involvement. The mode of death is homicide.



LISA SCHEININ, M.D.
DEPUTY MEDICAL EXAMINER

04/07/97
DATE

LS:rs:c
T-3/19/97

15

A B C
 EXAMINATION ONLY (0)
 Date 3/10/97 Time 1030 Dr. SCHERWIN
 PRINT NAME
 PENDING FINAL ON. 3/10/97
 TOX NEURO LAW ENF. REPORT
 HISTO MED HIST. OTHER

APPROXIMATE INTERVAL BETWEEN ONSET AND DEATH

LAPD/WILSHIRE

22. DEATH WAS CAUSED BY: (ENTER ONLY ONE CAUSE PER LINE FOR A, B, C AND D) IMMEDIATE CAUSE

(A) Gunshot Wound to Abdomen - Chest

upto 45 min

REQUEST

- Police Report
- Med. History
- Consultation
- Investigations
- Criminalistics
- GSR Other

DUE TO, OR AS A CONSEQUENCE OF

(B) DUE TO, OR AS A CONSEQUENCE OF

(C) DUE TO, OR AS A CONSEQUENCE OF

(D) DUE TO, OR AS A CONSEQUENCE OF

Other conditions contributing but not related to the immediate cause of death:

Multiple nonfatal gunshot wounds

NATURAL ACCIDENT SUICIDE HOMICIDE UNDETERMINED

If other than natural causes HOW DID INJURY OCCUR? Shot by assailant(s)

WAS OPERATION PERFORMED FOR ANY CONDITION STATED ABOVE? Yes No

TYPE SURGERY Thoracotomy DATE 3-9-97

ORGAN PROCUREMENT WITNESSES TO AUTOPSY: LAPD Wilshire Dets. Chavez + Balderrama

PERTINENT COMMENTS: 1:15:MR - 24 BM psgr in vehicle, shot in drive-by incident ~0030 hrs 3-9-97. Taken to ER of Cedars-Sinai Hosp. Thora-cotomy + debs done, no response. Pronounced dead at 0115. Bullet found @ hosp. when body turned over p pronouncement + given to police. (Arrived full arrest + agonal rhythm. Tcut -> lg amt bld chest + pericardium - all evacuated)

Per above Dets., these bullets recov. from hospital - on gurney
 Gsw @ elbow -> wrist @ bullet, not fatal
 ② Back -> L shoulder, no projec (T+T), not fatal
 ③ L thigh, T+T, not fatal
 ④ R mp -> L shoulder, @ bullet, FATAL
 Morbid obesity (395 lbs)

- HISTOPATH CUT: AUTOPSY LAB
- MICROBIOLOGY:
- NEUROPATHOLOGY

TOXICOLOGICAL SPECIMENS COLLECTED

- YES, by MS/LS
- BLOOD: HEART OTHER
- BILE BRAIN
- LIVER SPLEEN
- URINE minimal KIDNEY
- STOMACH CONTENTS VITREOUS
- Removal bld
- NO BLOOD
- EMBALMED
- > 24 HR. IN HOSPITAL
- NOT INDICATED
- OTHER

TOXICOLOGICAL ANALYSES ORDERED

- SCREEN: C H T S
- ALCOHOL ONLY
- CARBON MONOXIDE
- NO TOXICOLOGY REQUESTED
- OTHER (SPECIFY DRUG AND TISSUE)

STORAGE JARS (No. 1)

Typing Blood Taken by MS/LS

HEART OTHER

PRIOR EXAMINATION REVIEW BY DME

- BODY TAG MED. RECORD brief ER
- CLOTHING none AT SCENE PHOTO (NO.)
- SPECIAL PROCESSING TAG X-RAY (NO. 9)
- FLUORO

WHITE - FILE COPY
 CANARY - FORENSIC LAB COPY
 PINK - INVESTIGATION COPY
 GOLDENROD - MEDICAL EXAMINER COPY

RESIDENT

M.D.

Scherwin

DEPUTY MEDICAL EXAMINER

M.D.

DEATH CERTIFICATE ISSUED

DATE ISSUED ISSUED BY

DATE ISSUED ISSUED BY

16

Thoracot 61cs (L)

DEPT OF CORONER
111
LIFE/WILSONIRE

EXTERNAL EXAM

Sex M
Race B
Age 24
Height 74
Weight 395

see 20

Hair
Eyes
Sclera
Teeth
Mouth

Tongue H Reddg with 1/2 lac

Nose
Chest
Breasts
Abdomen

Scar
Genital
Edema
Skin

Decub 660↑

HEART Wt

Pericard bld, incised
+ Hypert R 0.4-0.6 L 1.7-2.1 S 2.0

Dilat φ
Muscle & fix lesion (nl EOT)
Valves nl
Coronar min AS, no signif sten

AORTA mild AS, High stng.

VESSELS nl

LUNGS Wt

R 690
L 600
Adhes φ
Fluid sm bld
Atelectasis φ
Oedema 2+
Congest 2+
Consol φ
Bronchi nl
Nodes nl

mod from pharynx tonsil
PHARYNX nl
TRACHEA nl
THYROID
THYMUS nl
symm. enlarged
wt 120g
no nodules

PERITONEUM

Fluid sm bld ≤ 50cc big clots.

Adhes φ

LIVER Wt 2280 r-br ↑

Caps nl EOT
Lobul ↓
Fibros ↓
GB 30-50cc. φ rigid & thick

Calc 5 yel munda soft ov. 0.4-0.6

Bile ducts nl

SPLEEN Wt 260 sl ↑ C

Color nl

Consist ↓

Caps ↓

PANCREAS

ADRENALS

KIDNEYS Wt

Caps nl
Cortex nl
Vessels nl
Pelvis nl
Ureter nl

BLADDER

GENITALIA

Prost nl
Testes nl 5 traume
Uterus
Tubes
Ovar

ESOPHAGUS

STOMACH

DUOD & SM INT

APPENDIX

LARGE INT

ABDOM NODES

SKELETON

Spine ↓

Marrow ↓

BRAIN Wt 1490

Dura nl
Fluid ↓ mild-
Ventric ↓ mod
Vessels ↓ 2
Ears
Nasal Sin

PITUITARY

Forms 20(3)
21

TOXICOLOGY

bld urine (min) bile
Sm bld liver stom

SECTIONS

XR - 9
Fluoro of ST neg
exc 2 bullets LUE

GROSS IMPRESSION

Markid obesity
C neg E BiVH
H neg S neg
SLP ortho rod, fem fx (L)
Cholelithiasis

Pulm 2

Gross (x4)

- ① C forearm, NF, ① bullet
- ② Back, NF, No projec
- ③ Posto med L thigh, NF
No projec
- * ④ R hip → L shldr
Fatal, ① bullet

SLP Thoracot + med/surg
intervention

UB Dets. Chavez + Balderrama present
They say 2 bullets recover from gunney at hosp.

Tech - M Johnson

te 03-10-97

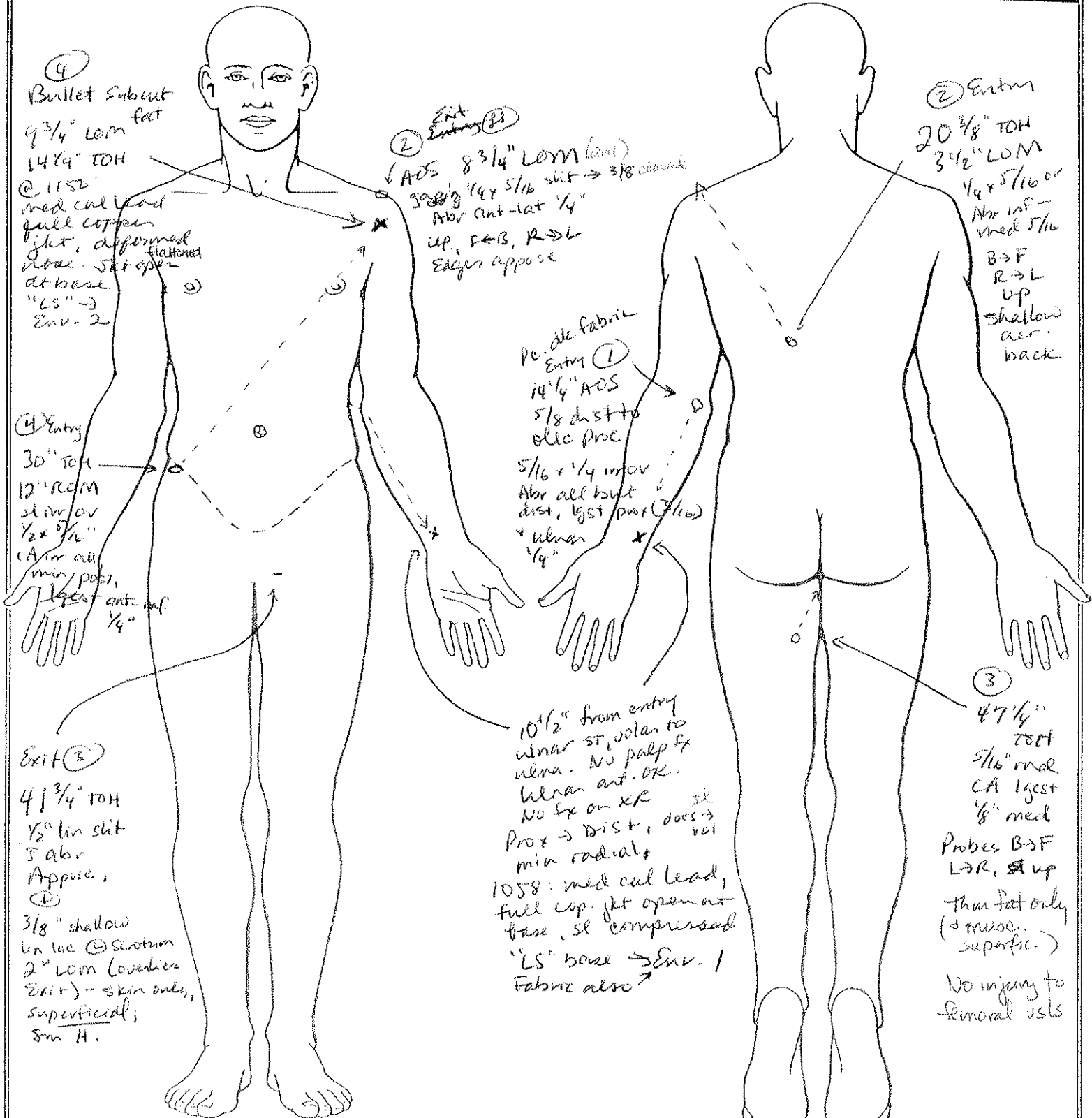
Time 1030-1320

Deputy Medical Examiner
S. Schmitt MD

20

10/3

No soot or stippling, at any entry.



④ Bullet Subcut

9 3/4" LOM
14 1/4" TOH

@ 1152
med cal lead
full copper
jkt, deformed
nose. Jkt open
at base
"LS" →
Env. 2

④ Entry

30" TOH
12" LOM
slim or
1/2 x 3/16"
CA in all
mm/ppt,
1/2" ant-inf
1/4"

Exit ③

4 1/4" TOH
1/2" lin slit
3 abv
Appose,

①
3/8" shallow
lin lac @ sternum
2" LOM (overlies
Exit) - skin only,
superficial;
8m H.

Exit Entry ②

② AOS 8 3/4" LOM (ant)
30 1/2" 1/4 x 5/16 slit → 3/8 closed
Abr ant-lat 1/4"
UP, R→B, R→L
Edges appose

Per. die fabric

Entry ①
14 1/4" AOS
5/8 dist to
olec proc
5/16 x 1/4 in ov
Abr all but
dist, 1/2" prox (7/16)
ulnar
1/4"

10 1/2" from entry
ulnar st, volar to
ulna. No palp fx
ulnar ant-OR.
No fx on XR
Prox → Dist, dors → vol
min radial
1058: med cal lead,
full cop. jkt open at
base, sl compressed
"LS" base → Env. 1
Fabric also →

② Entry

20 3/8" TOH
3 1/2" LOM
1/4 x 5/16 or
Abr inf -
med 5/16
B→F
R→L
up
shallow
over
back

③

47 1/4"
TOH
5/16" med
CA 1 gest
1/8" med
Probes B→F
L→R, up
Thin fat only
(+ muscle,
superficial.)
No injury to
femoral vsls

Scheiner

M.D.

3-10-97

Deputy Medical Examiner

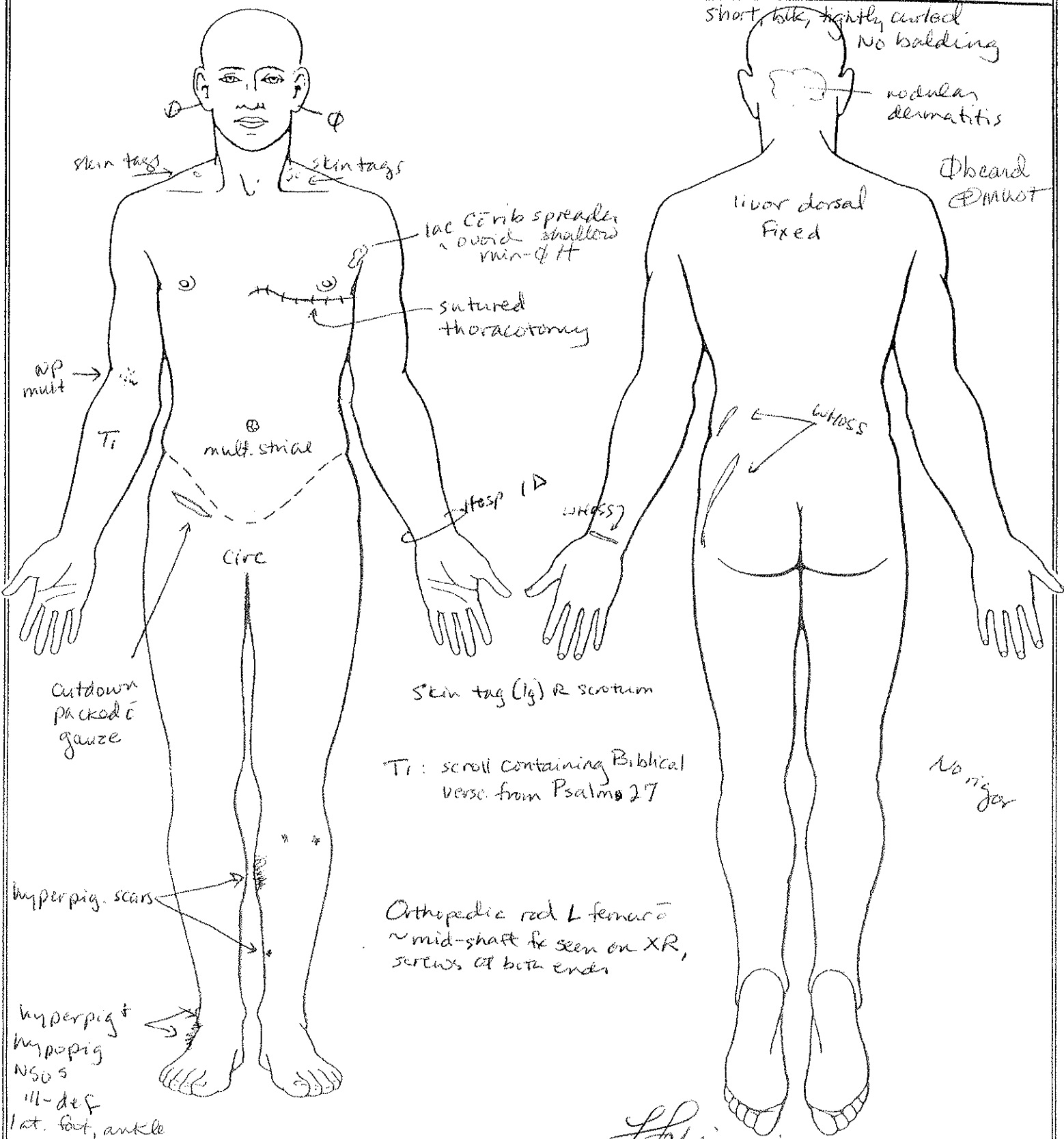
20

2 of 3

WD morbidly obese BM ± extremely protuberant abdomen

Eyes: born, PER, very injer, PH Bed nares Own teeth

PHOTOGRAPHIC RECORD
DATE OF EXAMINATION
TIME OF EXAMINATION
LIPID/ALCOHOL



short, thick, tightly curled No balding

nodular dermatitis

beard PHHOT

livor dorsal Fixed

lac. C ribs spreader ~ ovoid shallow min-QH

sutured thoracotomy

NP mult

Ti

mult. striae

stesp (D)

WHSS

WHSS

circ

Outdown packed gauze

skin tag (lg) R scrotum

Ti: scroll containing Biblical verse from Psalm 27

No rigor

hyperpig. scars

Orthopedic rod L femur ~ mid-shaft seen on XR, screws at both ends

hyperpig + hypopig NSOs ill-def lat. foot, ankle

Schmitt

M.D.

B-10-97

Deputy Medical Examiner

20

373

Entire track of (2) dissected from entry to exit. No entry to chest, no rib or scapular fr.

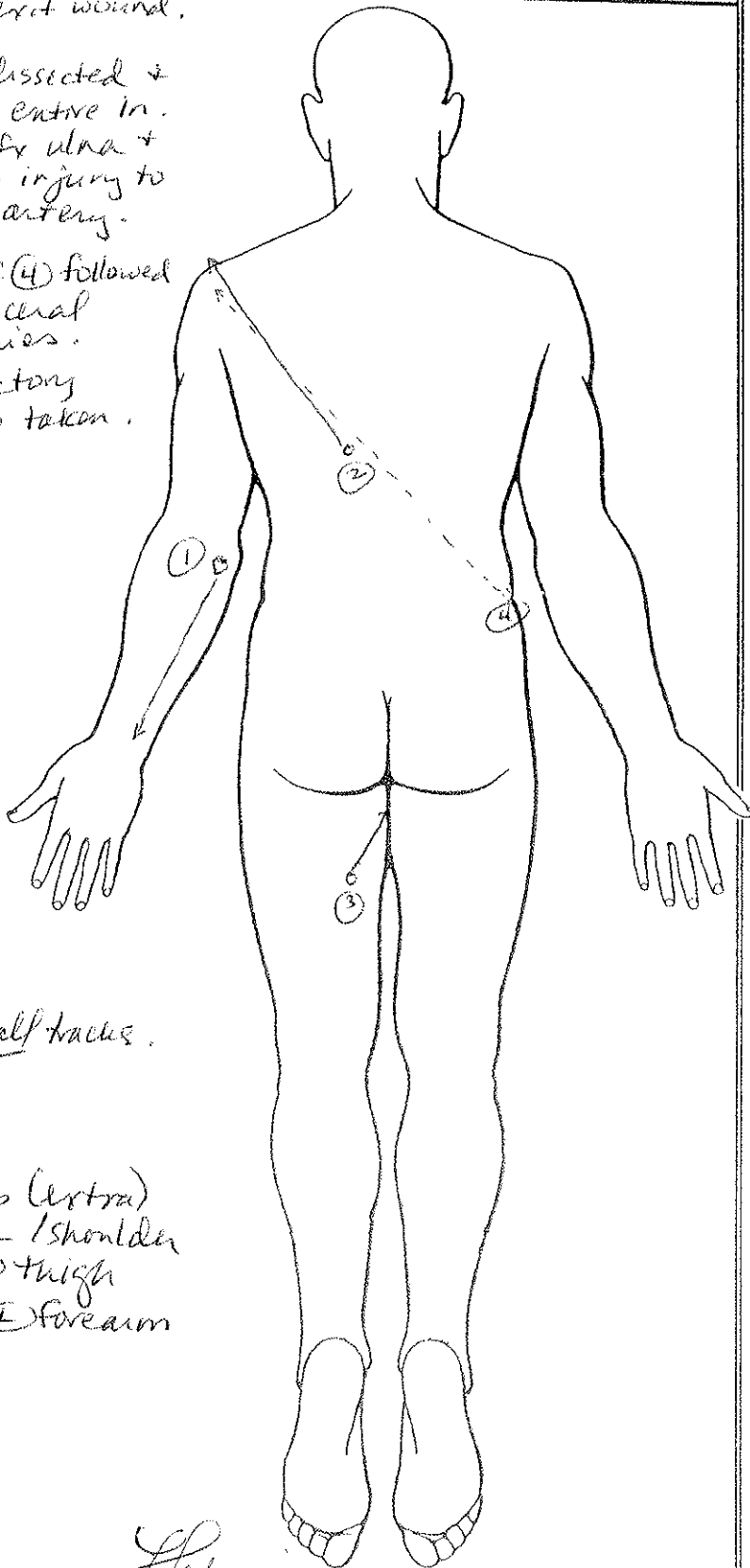
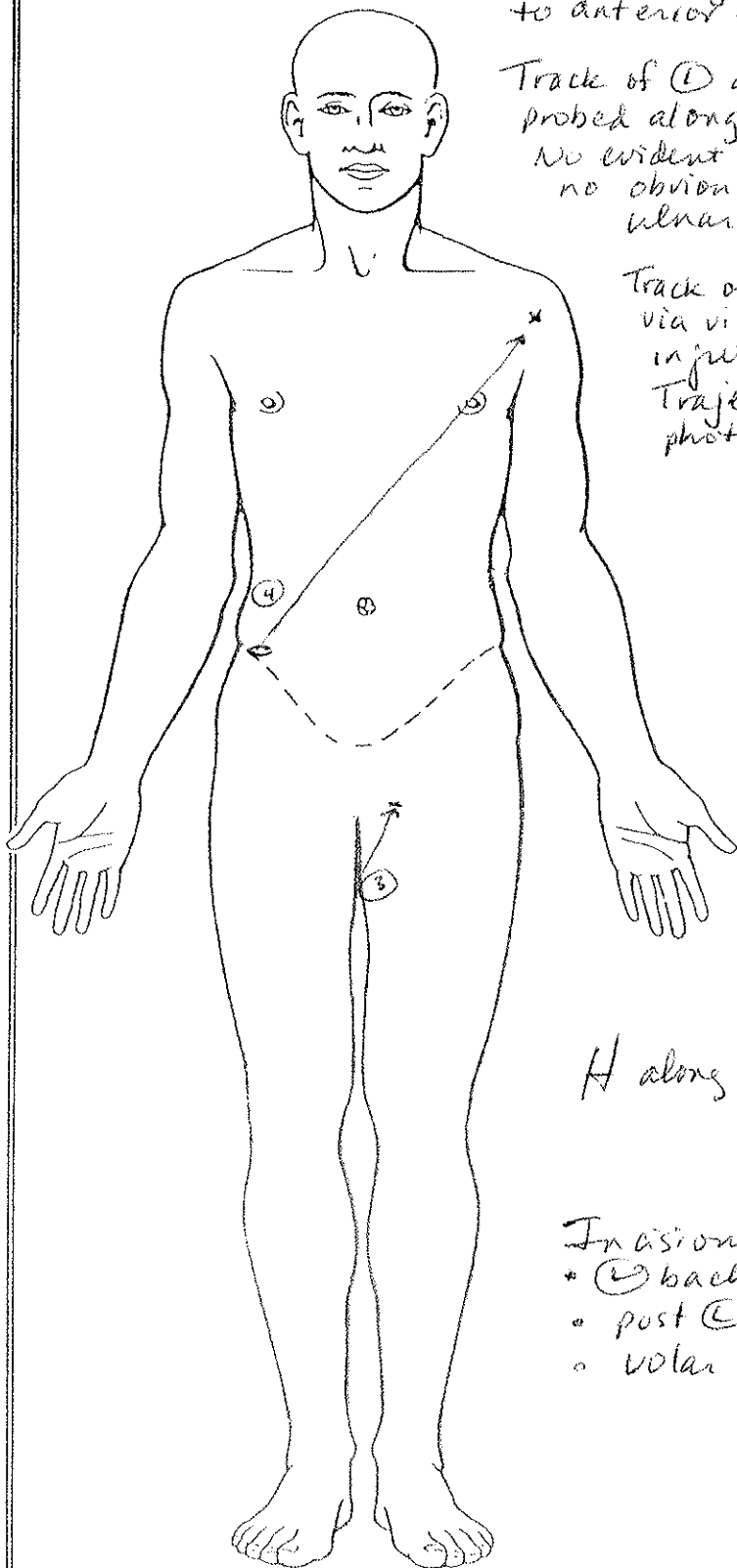
Track of (3) dissected through post. (L) thigh + probed to anterior exit wound.

Track of (1) dissected + probed along entire in. No evident fr ulna + no obvious injury to ulnar artery.

Track of (4) followed via visceral injuries. Trajectory photo taken.

97-01812

Wallace,
Christopher



H along all tracks.

- Incisions (extra)
- (L) back / shoulder
 - post (L) thigh
 - volar (L) forearm

Scheinin

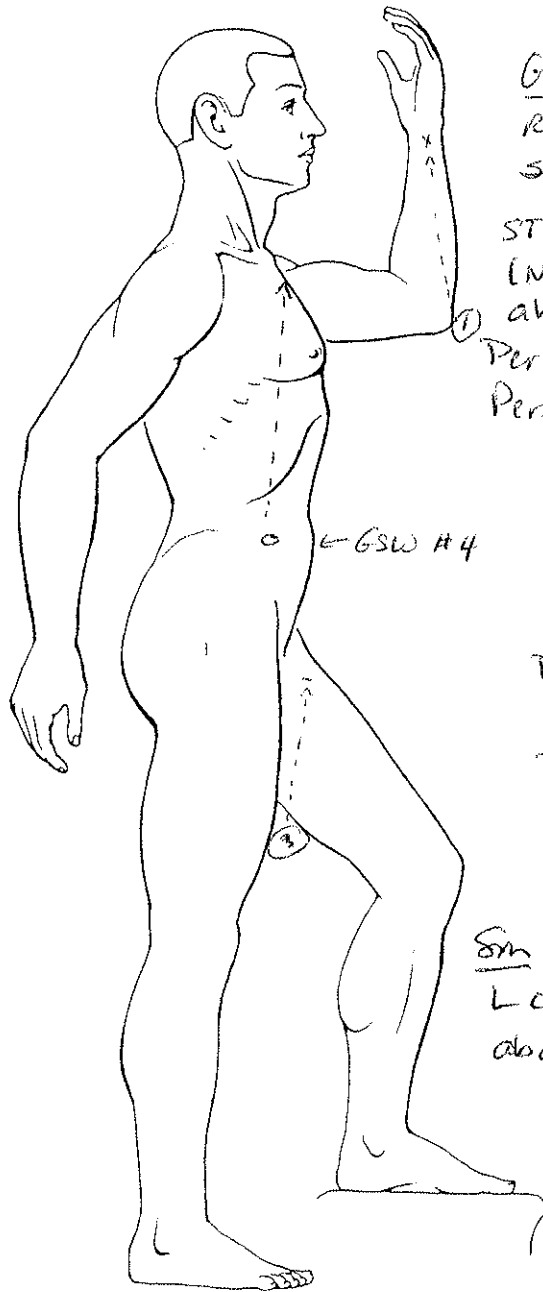
3/10/97

Deputy Medical Examiner

M.D.

21

97-01812
WALLACE, Christopher



Rt

GSW 4
R to L, up,
SL B to F

ST R hip area
(no pelvic fx) ->
abdomen

Perf (2 holes) asc colon

Perf liver inf -> sup

R diaph, PC

Enters heart at RA
near IVC, perforates ventric
septum subvalv. area,
exits ant LV wall

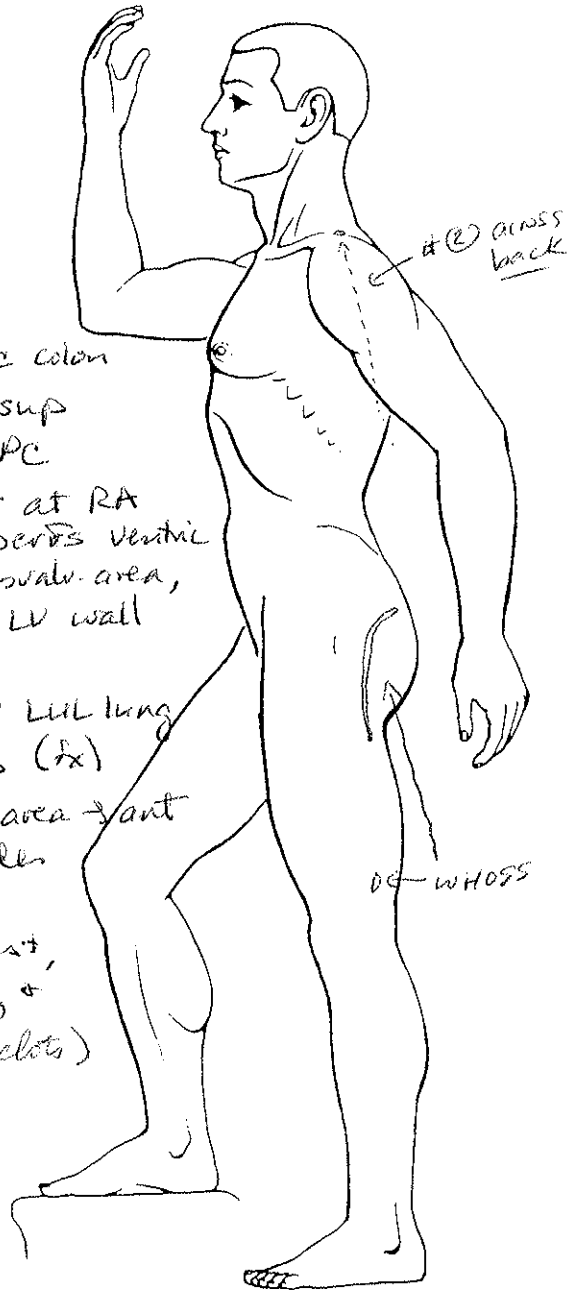
Perfs PC

Perfs medial LUL lung

Thru (L) 3 ribs (fx)

ST pectoral area -> ant
L shoulder

Sm lig bld R chest,
L chest, PCard, +
abdomen (+few clots)



Lt

3-10-97

L. Scheinin

Deputy Medical Examiner

M.D.

Report of Toxicological Analyses
Department of Coroner
County of Los Angeles

03/25/97

Non-Pending

TO: Lisa A. Scheinin, M.D.
Deputy Medical Examiner

FROM: Forensic Toxicology Laboratory
Forensic Science Laboratories Division

SUBJECT: Coroner's Case Number 97-01812 SWALLACE, CHRISTOPHE R

In accordance with your request, toxicological analyses have been performed and are now completed on the subject case as tabulated below:

Tissue	Analyses Requested	Drugs Analyzed	Level Found	Assigned Toxicologist	Date Analyzed
Blood	Alcohols	Alcohols	Negative	J. Park	03/12/97
Blood	Cocaine	Cocaine and Metabolites	ND	M. Schuchardt	03/17/97
Blood	Narcotics	Codeine	ND	M. Schuchardt	03/17/97
Blood	Narcotics	Morphine	ND	M. Schuchardt	03/17/97
Blood	Phencyclidine	Phencyclidine	ND	M. Schuchardt	03/17/97
Blood	Methamphetamine	Methamphetamine	ND	S. Winter	03/21/97

LEGEND:

MG/L = Milligram per Liter
UG/ML = Micrograms per Milliliter
QNS = Quantity Not Sufficient
UG/G = Micrograms per Gram
MG/DL = Milligram per Deciliter
TNP = Test Not Performed

G% = Gram Percent
ND = Not Detected
MG = Milligrams

JOSEPH J. MUTO
CHIEF FORENSIC TOXICOLOGIST

1 B

POST MORTEM AT:

- MEC/FSC
- MORTUARY
- OTHER FACILITY

REPORTED AS:

- Natural
- Accident
- Suicide
- Homicide
- At Work
- Nursing Home
- In Custody
- State Hosp.

CASE NO. 97-01812

DECEDENT IDENTIFIED BY:

LAST NAME Wallace
 FIRST Christopher MIDDLE —
 Age 30 DOB 5-26-74 MALE FEMALE

CROSS REFERENCE TO:

RACE APPEARS BLK

PLACE OF DEATH - NAME OF FACILITY STREET ADDRESS ZIP CODE

CEDAR S. ANI

DATE OF DEATH - Month, Day, Year 3-9-97 HOUR 0115 FOUND OR PRONOUNCED BY SILKA SCENE PHONE ()

Usual Residence UNK ZIP CODE

Reported by Berchem Agency LAPD/Wilshire Hq. Phone (213) 485-4033

Reported to M.E.C. [Signature] Date/Time 3-10-97 0430 847-3990

Investigating Agency RHD Officer [Signature] DATE TIME 3-9-97

Next of Ki: Relationship

Street Address Phone

City State 6345 ZIP CODE

Notified by [Signature] DATE TIME

DESCRIBE TERMINAL EPISODE AND OTHER PERTINENT INFORMATION:

MULT - GSW
Fairfax & Wilshire 3-8-97 2300hrs

NOTE # Decedent 400 + LOS

Decedent may be Rap Singer

EVIDENCE REQUESTED: HAIR FINGERNAIL GSR OTHER

Hospital paperwork ready Date Time 1-9-97 Per [Signature] POLICE REPORT #

THIS SECTION FOR INQUIRY ONLY

Attending Physician Phone

Address LAST DATE ATTENDED

CAUSE OF DEATH	107. DEATH WAS CAUSED BY: (ENTER ONLY ONE CAUSE PER LINE FOR A, B, C, AND D)	TIME INTERVAL BETWEEN ONSET AND DEATH	108. DEATH REPORTED TO CORONER <input type="checkbox"/> YES <input type="checkbox"/> NO REFERRAL NUMBER
	IMMEDIATE CAUSE (A)		109. BIOPSY PERFORMED <input type="checkbox"/> YES <input type="checkbox"/> NO
	DUE TO (B)		110. AUTOPSY PERFORMED <input type="checkbox"/> YES <input type="checkbox"/> NO
	DUE TO (C)		111. USED IN DETERMINING CAUSE <input type="checkbox"/> YES <input type="checkbox"/> NO
DUE TO (D)			

112. OTHER SIGNIFICANT CONDITIONS CONTRIBUTING TO DEATH BUT NOT RELATED TO CAUSE GIVEN IN 107

113. WAS OPERATION PERFORMED FOR ANY CONDITION IN ITEM 107 OR 112? IF YES, LIST TYPE OF OPERATION AND DATE

Discussed With , M.D. By Deputy

Date & Time Mortuary Notified

SUPPLEMENTAL INFORMATION BY: Approved

#97-01812

18

TO REPORT A DEATH---PHONE (213) 343-0711
COMPLETE ALL LINES. USE INK. IF UNKNOWN OR NOT APPLICABLE.
SO STATE.

CEDARS-SINAI MEDICAL CENTER

NAME OF FACILITY

001/000966265

WALLACE, CHRISTOPHER

M/99/99/999

DOS 03/09/97

ER 999/999/999 AGE 23 SEX M RACE BLK

999/999/999 E EM

HOSP. OR I.D. NO. 000966265

ADDRESS 8700 Beverly Blvd.

PHONE (213) 855-5452

NAME OF DECEDENT **WALLACE, Christopher**

DATE OF DEATH **3-9-97** TIME **0115 AM**

PRONOUNCED BY **Dr. PAUL SILKA**

EMERGENCY ROOM PATIENT

HOSPITAL IN PATIENT

ORGAN/TISSUE DONATION INFORMATION

WAS THE NEXT OF KIN APPROACHED REGARDING ORGAN/TISSUE DONATION?
NO YES IF YES WHAT WAS THEIR RESPONSE?

DATE ADMITTED **3/9/97**

TIME **0115**

TO HOSPITAL BY: POLICE RELATIVES FRIENDS SELF AMBULANCE (Name or R.A. #)

FROM (STATE WHETHER HOME, HOSPITAL OR OTHER) GIVE ADDRESS (IF HOSPITAL ATTACH THEIR HISTORY)

ADMITTED BY: M.D. ATTENDING PHYSICIAN M.D.

INJURIES **3/9/97** **0000** PLACE CAUSE (TRAFFIC, FALL, ETC.)

DESCRIBE INJURIES:

CLINICAL HISTORY:

SURGICAL PROCEDURES: STATE TYPE, DATE, TIME AND RESULTS OF ANY OPERATION OR AMPUTATION PERFORMED

WAS A BULLET OR OTHER FOREIGN OBJECT RECOVERED? SPECIFY

*unknown kind of bullet found to
police officer McKinney badge # 27422*

LABORATORY: SPECIFY SPECIMENS TAKEN

LABORATORY RESULTS:

DATE & TIME **3/9/97 0115 AM**

RETAIN LABORATORY SPECIMENS

X-RAY REPORT:

REMARKS: ESPECIALLY SYMPTOMS PRECEDING AND DURING TERMINAL EPISODE

IN MY OPINION, THE IMMEDIATE CAUSE OF DEATH IS:

*Cardiopulmonary arrest
multiple gunshot wounds
traumatic asphyxia*

BY **Paul A. Silka** M.D.

OR

OTHER OFFICIAL